

Two and Three Dimensional Wall Motion Analysis

Yasuhiko Abe, Hiroyuki Ohuchi, Tetsuya Kawagishi
Toshiba Medical Systems



Yasuhiko Abe Hiroyuki Ohuchi Tetsuya Kawagishi

Introduction

Echocardiography is increasingly used as a tool for analysis of cardiac function and as an aid to assessment of ischemia, dyssynchrony, heart failure and other cardiac conditions. Automatic Cardiac Output Measurement (ACM), Tissue Doppler Imaging (TDI) and Automatic Contour Tracking (ACT) have proven useful for these tasks, but now a new class of solution utilizing Wall Motion Tracking promises significant advances.

The validity of cardiac function assessment using TDI has already been well investigated. There are potential advantages to using B-Mode image data to generate the same results but image quality and processing power limitations have made this difficult. Now, improved image quality and new more powerful processing techniques make it possible to use an evolution of ACT to track and quantify myocardial movement in 2D image data and 4D volumes.

Wall Motion Tracking Technology

Two Dimensional Tracking (2DT) is an application of pattern matching technology to Ultrasound Cine data also commonly known as Speckle Tracking. A template image is created using a local myocardial region in the starting frame of the image data. In the next frame an algorithm searches for the local speckle pattern that most closely match the template (Fig. 1). A movement vector is then created using the location of the template and the matching pattern in the subsequent frame. Multiple templates are used to observe movement of the entire myocardium. The process is then repeated by creating new templates and observing their movement in the subsequent frames until the

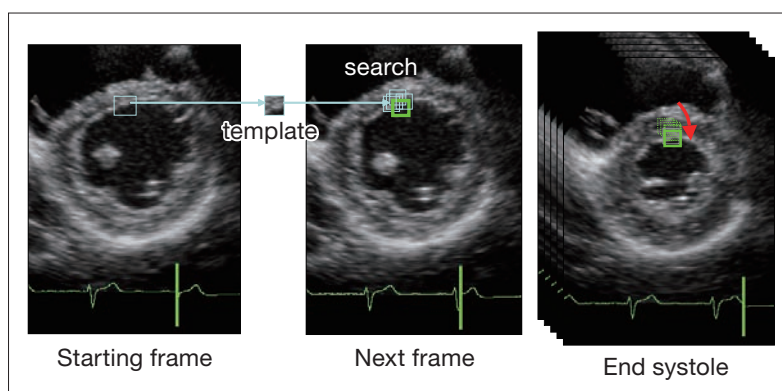


Fig. 1 2 Dimensional Pattern Matching

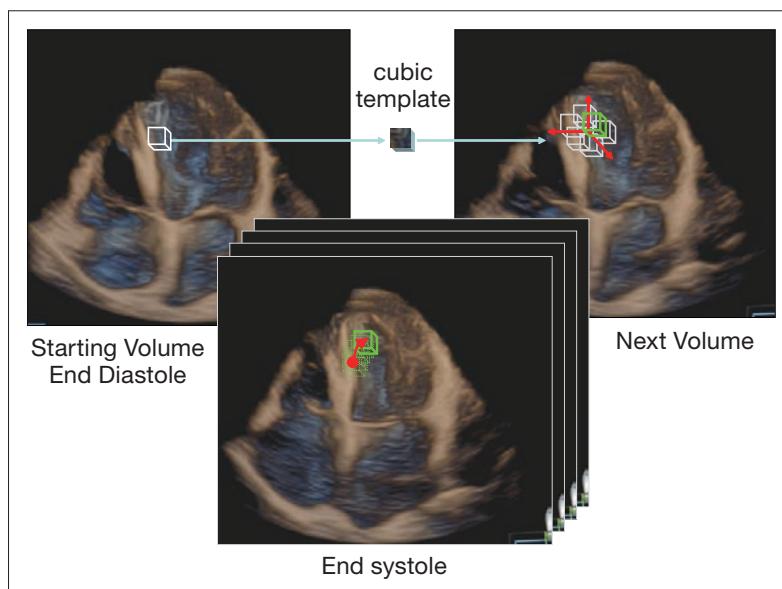


Fig. 2 3 Dimensional Pattern Matching

$$\text{Strain} = \frac{(L - L_0)}{L_0} \times 100 [\%]$$

Fig. 3 Strain Calculation

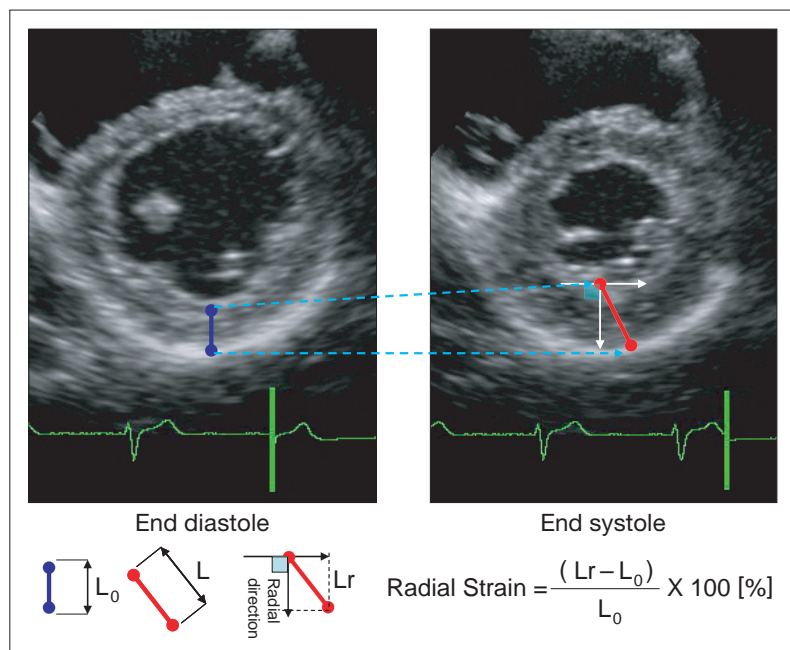


Fig. 4 Strain Calculation with Wall Motion Tracking

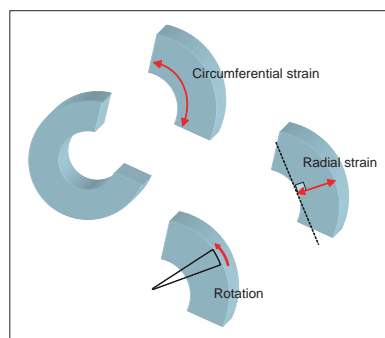


Fig. 5 Wall motion Parameters in SAX image

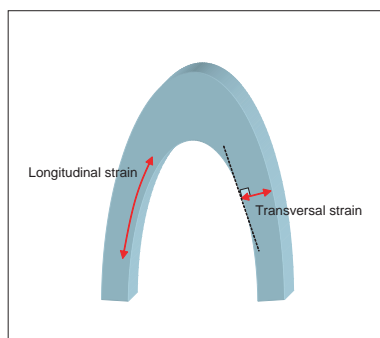


Fig. 6 Wall motion Parameters in Apical 4/3/2 Ch image

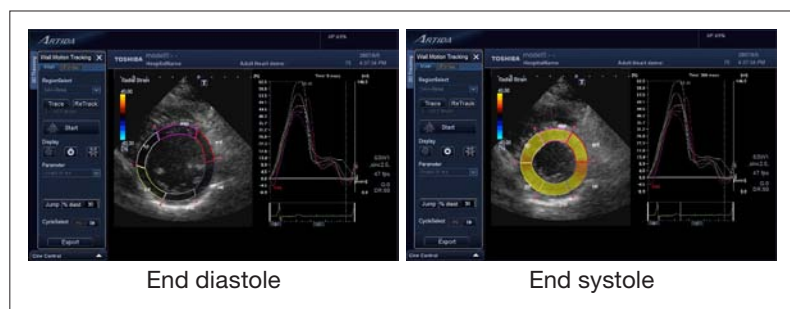

Fig. 7 Parametric Imaging of Strain

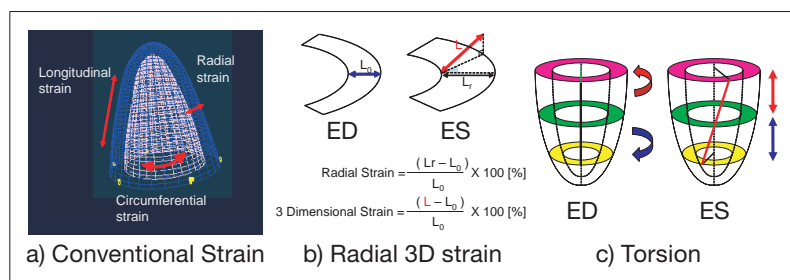


Fig. 8 Wall motion Parameters in 3D data

entire cardiac cycle has been assessed. This method does not make use of Doppler information, so there is no Doppler angle dependency.

Cardiac motion is 3 dimensional, so 2DT is limited because it cannot assess movement in the 3rd dimension. The same technique used in 2DT can be applied to 4D data by tracking 3 dimensional cubic templates through the cardiac cycle (Fig. 2). Three Dimensional Tracking (3DT)¹⁾ is a new application that can be used for regional Wall Motion Analysis of the entire Left Ventricle. 3DT can be used for real 3D indices (like torsion) and 3 dimensional wall motion assessment rather than assessment based on 2 dimensional projections of motion.

Strain Calculation using Tracking Results

Strain is a measurement of deformation representing shortening or expansion (Fig. 3). Because it is not affected by translational motion of the heart, strain offers a clear advantage over velocity and displacement for assessment of myocardial function. Radial, transversal, longitudinal and circumferential strain can be used for assessment of cardiac motion.

To calculate strain, a pair of points are defined in the initial frame. In subsequent frames the movement of the points is calculated using Wall Motion Tracking. The change in displacement between the two points is measured and calculated as a percentage of the displacement between the points in the initial frame. Thus strain values can be calculated in any frame. Fig. 4 shows a radial strain calculation for the end systolic frame.

Strain can be calculated, in different directions, using components of the displacement. For example radial strain is the relative change of the component of displacement perpendicular to the endocardium in the short axis view. In the short axis view, radial strain and circumferential strain can be calculated (Fig. 5). In the apical 4, 3 and 2 chamber views, transversal strain and longitudinal strain can be calculated (Fig. 6).

Fig. 7 shows an example of strain calculated using 2DT. Strain values of the local myocardium are color coded and superimposed on the image. Wall Motion Tracking not only provides strain values but can also generate rotation, strain rate and other values.

2DT calculates these values as a projection of 3D motion. But heart motion is 3 dimensional. 3DT can assess this motion in 3 dimensions and calculates 3 dimensional strain and other parameters for the whole Left Ventricle (Fig. 8). For example, calculation of torsion requires the rotation values of two short axis planes in the same cardiac cycle and the distance between the two planes must be known. Both the imaging of two planes and the measurement of the distance between the planes is hard to do with 2D technology.

Fig. 9 shows an example of strain calculated using 3DT. 3DT can provide different kinds of parametric imaging, mapped onto 3 dimensional wall segments with or without motion vectors and superimposed on multiplanar reconstructions.

Wall Motion Tracking results can also be displayed as a Dyssynchrony Imaging (DI) map. In DI display mode wall motion parameters (like time to peak strain) are color coded and displayed on the myocardium. Table 1 shows all the parameters calculated by 2DT and 3DT and the parameters which can be used for DI.

Validation

Validation efforts for 2D and 3D Wall Motion Tracking are being conducted by Dr. Lima at Johns Hopkins University and Dr. Seo at Tsukuba University using Toshiba's Artida™. Current results are shown in Fig. 10. Both 3DT and 2DT Wall Motion Tracking shows good correlations with MRI tagging analysis. Wall Motion Tracking has shown good correlation with conventional wall motion analysis²⁾ and numerical models³⁾.

Clinical Applications

Wall Motion Tracking is useful for the objective diagnosis of angina⁴⁾. Fig. 11 shows its application in Stress Echo. The Ischemic region exhibits decreased radial strain at peak (Fig. 11a and b). Diastolic Dyssynchrony is still clearly visualized, 5 minutes after stress. Using Diastolic Dyssynchrony, ischemic regions can be visualized after peak stress when the image is no longer as affected by heavy breathing and rapid heart rate. Application of Diastolic Dyssynchrony in unstable angina with 2DT is reported in ACC 2008⁵⁾.

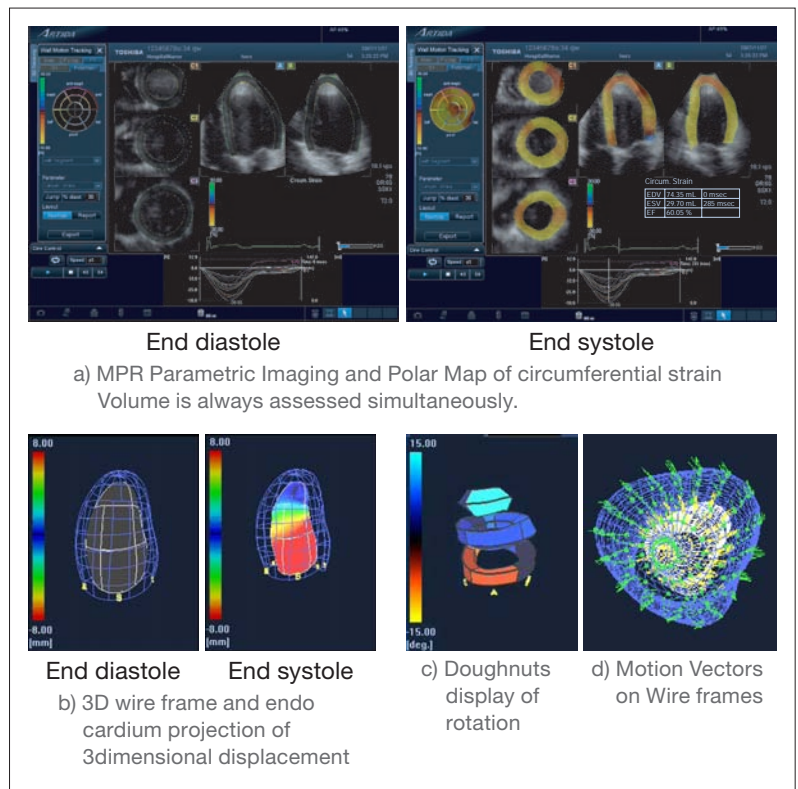


Fig. 9 Parametric Imaging of Strain with 3D Tracking

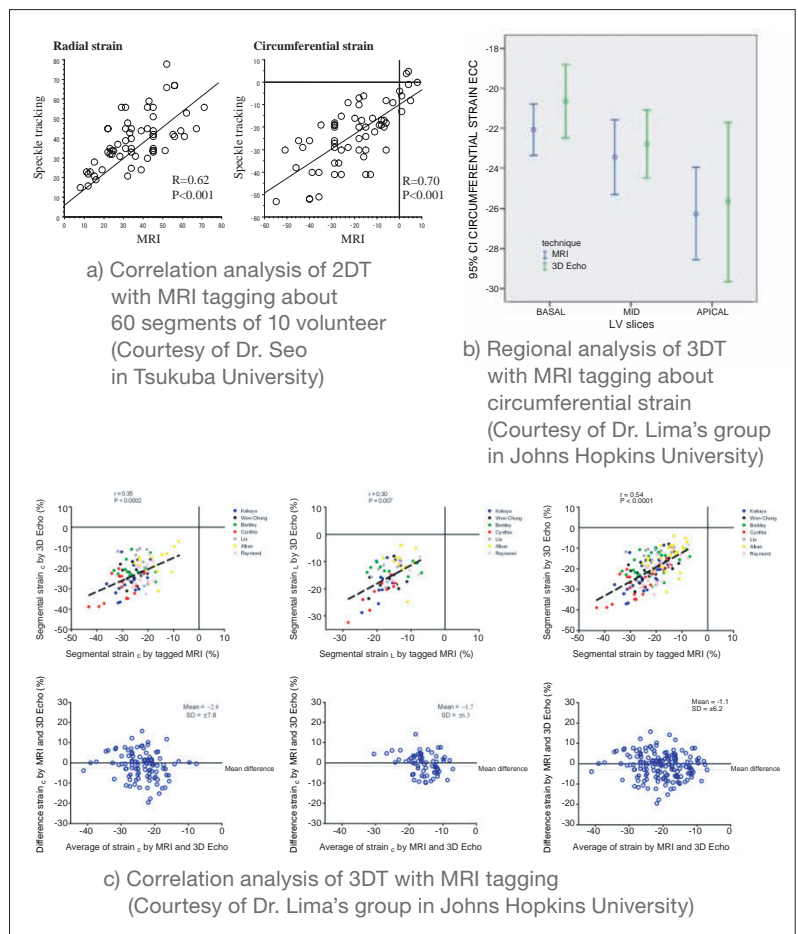


Fig. 10 Validation Results

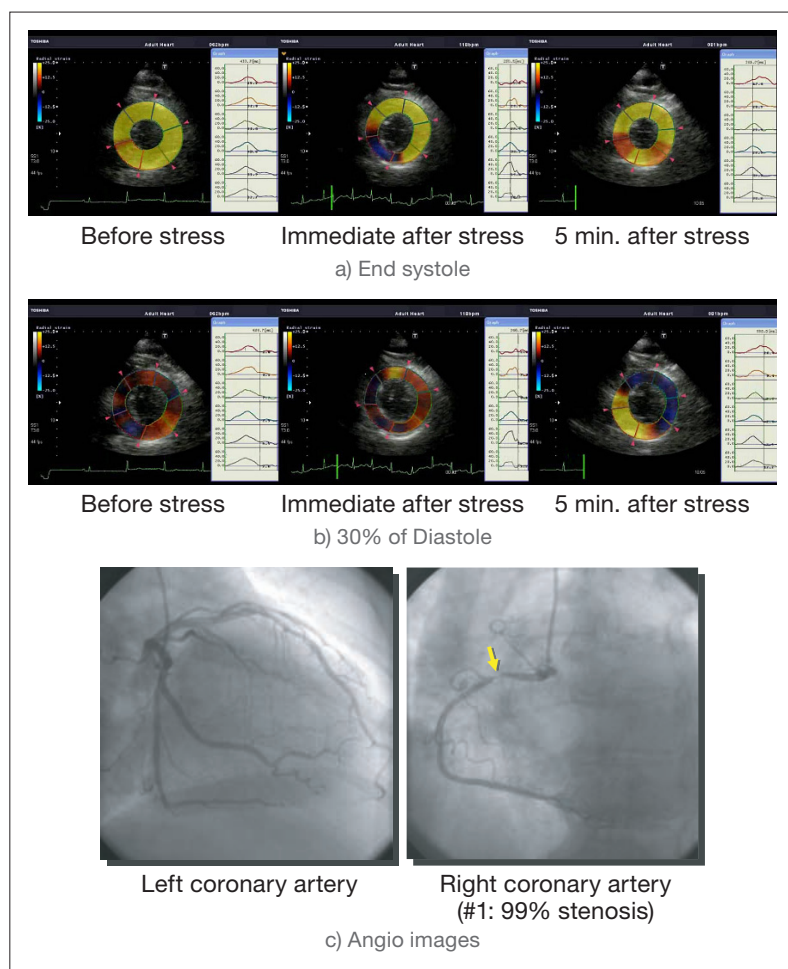


Fig. 11 Detection of Ischemia
(Courtesy of Dr. Ishii in Kansai-Denryoku Hospital)

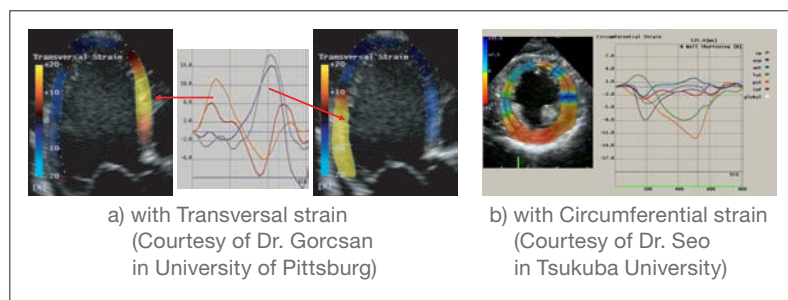


Fig. 12 Dyssynchrony Estimation

| | (2D Tracking for SAX) SAA Tracking SAx Tracking SAB Tracking | (2D Tracking for Apical approach) 4Ch Tracking 2Ch Tracking 3Ch Tracking | 3D Tracking |
|-----------------------|---|--|---|
| Wall Motion Parameter | Radial Strain Radial Strain Rate Radial Displacement Radial Velocity Circumferential Strain Circumferential Strain Rate Rotation Rotation Rate | Longitudinal Strain Longitudinal Strain Rate Longitudinal Displacement Longitudinal Velocity Transversal Strain Transversal Strain Rate Transversal Displacement Transversal Velocity | 3D Dimensional Strain 3D Dimensional Displacement Radial Strain Radial Displacement Longitudinal Strain Longitudinal Displacement Circumferential Strain Rotation Twist Torsion (from basal) Regional Torsion |
| DI Parameter | Radial Strain Radial Displacement Circumferential Strain | Longitudinal Strain Longitudinal Displacement Transversal Strain Transversal Displacement | Longitudinal Displacement |

Table 1: Wall motion Parameters provided by WMT

Wall Motion Tracking is also expected to contribute to dyssynchrony estimation in CRT[®]. Segmental analysis is preferred for wall motion assessment. In Fig. 12 a segmental strain over time graph is displayed. Average values for each segment are shown. 2 cases are shown in which peak strain in different segments is at very different points in the cardiac cycle. Dyssynchrony is easily recognized.

2DT is now quite well studied and is finding its way into clinical routine. 3DT is generating new functional information and is at the forefront of a new area of clinical research into cardiac wall motion.

Reference

1. US Patent filed, Pub. No.: US2003/0171668A1, (2003); H. Tsujino, M. Nishiura
2. Usefulness of Automated Quantitation of Regional Left Ventricular Wall Motion by a Novel Method of Two Dimensional Echocardiographic Tracking, Am J Cardiol Vol. 98, Issue 11, 1531-1537 (2006); K. Ogawa, T. Hozumi, K. Sugioka, Y. Matsumura, M. Nishiura, R. Kanda, Y. Abe, Y. Takemoto, M. Yoshiyama, J. Yoshikawa
3. Accurate Detection of Regional Contraction Using Novel 3-Dimensional Speckle Tracking Technique, JACC Vol. 51, No. 10 (Supplement A) 903-253, A116 (2008); Y. Abe, T. Kawagishi, H. Ohuchi, T. Takeguchi, M. Nishiura
4. Detection of Postischemic Regional Left Ventricular Diastolic Dyssynchrony after Exercise-Induced Ischemia in Patients with Stable Effort Angina by Using Strain Image Derived From 2D Speckle Tracking, JASE Vol. 20, No. 5 Abstracts 561 (2007); K. Ishii, T. Sakurai, K. Kataoka, M. Imai
5. Noninvasive Diagnosis of Acute Coronary Syndrome Among Patients with Chest Pain by Echocardiographic Detection of Postischemic Regional Left Ventricular Diastolic Dyssynchrony using Strain Image Derived from 2D Speckle Tracking, JACC Vol. 51, No. 10 (Supplement A) 901-280, A104 (2008); K. Ishii, T. Nagai, T. Sakurai, M. Imai, T. Suyama, M. Kawanami
6. Validation of Novel Echocardiographic Speckle Tracking Radial Strain To Assess Ventricular Dyssynchrony: Comparison with Angle Corrected Tissue Doppler Strain Imaging, JACC Vol. 49, No. 9 (Supplement A) 806-8,100A (2007); M. Tanabe, M. S. Suffoletto, M. R. Pinsky, J. Gorcsan, III

*Artida is trademark of Toshiba Medical Systems Corporation.